

The Evaluation of Pulmonary Solid Nodules for Resection Surgery

Giorgio Maria Paolo Graziano, Antonio Di Cataldo, Antonino Graziano

Abstract— Introduction Pulmonary neoplasia is diagnosed or advanced, or when the radiological appearance of the neoplasm leaves little doubt. Lung cancer is the most common in men with 16% of all tumors and an epidemiological increase in the neoplasm that in recent years has achieved a mortality that has increased progressively, reducing only in the last decade in Europe because of the continuous anti-smoking campaigns. The study aims to address the controversial controversies on the characteristics of the pulmonary nodule with the proposal of a diagnostic algorithm adopted by us in clinical practice to obtain an early diagnosis and in a short time Materials and methods January 2017 to December 2017 at the II Clinical Surgery and Polyclinic II University of Catania presented to our observation n 7 patients aged between 4 and 60 years old age 50 years of which 4 males and the remaining 5 female patients . In patients with suspected small pulmonary nodule the information obtained was based on a chest radiograph and a subsequent CT scan. Results The discussion of the morphology of the pulmonary nodule studied with diagnostic method for CT images the prevailing morphological characteristic was the diameter of the lesion that oscillated on average between 3-4 cm, and the criteria adopted did not clarify with accuracy the nature of the solid formation but hypothesize the benign or malignancy of suspicious lesions. Below these minimum diameters we obtained a safety with TC and RNM methods only in 50% of the observed cases, so in consideration of the high number of cases that were unresolved it was preferable to use more effective diagnostic methods. Discussion In the presence of solitary or multiple pulmonary nodules they have proved effective in obtaining a diagnosis according to the literature and also in our experience, in the first phase the simple but sensitive dynamic CT test, which oriented the diagnosis towards the benignity of the nodule for the presence of an increase in density after administration of the MDC that was less than 15-20 HU. PET proved to be a more accurate instrumental examination in the characterization of the nodule. Introducing the analysis of the metabolic behavior of the lesion studied, integrating the data provided by the CT. Conclusions Diagnostic imaging has improved accuracy by reducing diagnostic doubt only in those nodular lung lesions above > 2 cm. Radiological criteria for defining mediastinal lymph nodes are essentially the size and the morphological appearance.

Index Terms— Pulmonary nodules diagnosis.

I. INTRODUCTION

Highlight Pulmonary neoplasia is diagnosed or advanced, or when the radiological appearance of the neoplasm leaves

Giorgio Maria Paolo Graziano, University of Catania, Medical School Italy Dpt Sciences Medical of Surgery and Technologies Advanted via S Sofia 86 cap 95125 Catania

Antonio Di Cataldo, University of Catania, Medical School Italy Dpt Sciences Medical of Surgery and Technologies Advanted via S Sofia 86 cap 95125 Catania

Antonino Graziano, University of Catania, Medical School Italy Dpt Sciences Medical of Surgery and Technologies Advanted via S Sofia 86 cap 95125 Catania

little doubt. Lung cancer is the most common in men with 16% of all tumors and an epidemiological increase in the neoplasm that in recent years has achieved a mortality that has increased progressively, reducing only in the last decade in Europe because of the continuous anti-smoking campaigns (1,2,3,4) The disease is particularly common in northern Europe, USA or in the eastern countries. smoking remains the main responsible (80-90%) of the cases of neoplasia, as well as the prolonged abstinence of tobacco is able to affect life span. (5,6,7,8) Passive smoking is also responsible for the highly polluting tobacco combustion products causing 500 deaths per year in the USA. Atmospheric pollution is also associated as a risk factor due to the presence of carcinogenic factors as well as genetic predisposition highlighted by the presence of genetic polymorphisms. The presence in the diet of vit A C E, dried fruits reduce the risk of contracting the disease. 5-year survival and 14% for males and 1 8% for women. (9,10,11,12) The current diagnostic imaging already in the early stages of lung disease making it essential to establish both the correctness of the tumor site and the confirmation of the clinical suspicion. The study aims to address the controversial controversies about the characteristics of the pulmonary nodule with the proposal of a diagnostic algorithm adopted by us in clinical practice to get an early diagnosis and in a short time

II. MATERIALS AND METHODS

January 2016 to December 2017 at the Polyclinic University of Catania we present 37 patients between the ages of 45-65 years of age 55 years of age, 27 of whom were male and the remaining 10 were female sex. Patients were admitted with suspected small pulmonary nodule. the information obtained was based on a chest radiograph(fig 1) and a subsequent CT scan.(fig 2)

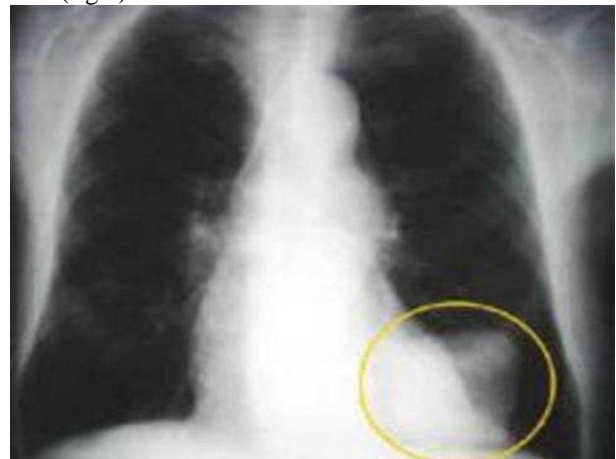


Fig 1 Rx torax nodules solid

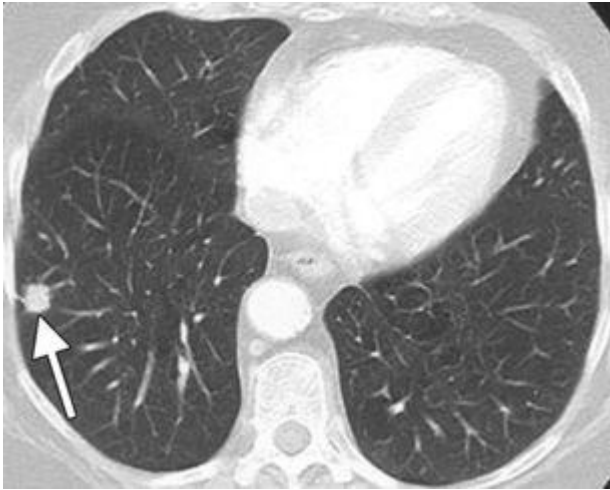

fig 2 TC torax nodules solid

The clinical suspicion was placed in most cases in the presence of metastatic disease. the diagnostic phase required the use of a sequential approach that involved the comparison of diagnostic imaging methods and haematological tests as well as the typing of the nodule. Radiological examinations evaluated the characteristics of the nodule > 2 cm, 1) Margin of the nodule 2) the presence of calcifications within it, 3) the involvement of adjacent structures with the relations with the examined nodule 4) the stability of the lesion over time (2 years), 5) the only peripheral lesion, 6) the presence of atelectasis, 7) the pleural effusion. for lesions lower than 2 cm up to a maximum diameter of 7mm: the metabolic aspects of the lesion (PET) were evaluated. the confirmation of the nature of the suspected lesion occurred through the histological examination which in 70% of cases was sufficient to establish the nature of the lesion. In the remaining 30% due to the very small size, a waiting time of three months was preferred, followed by a biopsy excision if the dimensions were increased. The CT contrasted the TNM and the parameters taken into consideration were: of the lesion, in addition to the shape, the density, the vascularization of the lesion and the increase over time. the assessment included the study of the abdomen with a visualization of the kidney and adrenal gland, the evaluation of the brain remained the subject of discussion, which in our clinical practice we perform with the detection of brain MTS in 50% of cases, as a late diagnosis. In the indication to the execution of the PET the examination has shown its reliability in the characterization of the lesions (active or not) and in the repression and in the follow-up. For the typing of the pulmonary lesion in addition to the histological examination of the sputum (3 samples) that is still sensitive, the aspiration needle was performed with a percutaneous technique, bronchoscopy with the collection of cellular material, bronchial endo biopsies, peri biopsies. bronchial, excisional biopsies performed with the VAT technique that in expert hands allowed diagnosis. the diagnostic difficulties were due to the lesion typing procedure in relation both to the neof ormation site (at the central or peripheral site) and to the size (<to 2 cm). For endoscopically visible central lesions, bronchoscopy was sufficient to obtain the cytology useful for diagnosis. For peripheral lesions the percutaneous route was preferred with indication to the invasive diagnostic procedure for patients candied with surgery or with impaired lung function. In the presence of lower lesions (<2 cm) the

surgical biopsy by typing was performed with a less invasive VAT method, after identification through PET which confirmed the suspicious nature of the lesion. The thoracotomy remained the surgical procedure adopted with diagnostic and therapeutic indication that included the pulmonary resection, when the images appeared to be multiple "frosted glass", in a single lobe of difficult classification, (30% of the cases). Finally, for lesions of 10mm in diameter we opted for a close serial control. Having obtained the diagnosis of neoplasm, it was necessary to define the prognostic factors, for which the study of the biomolecular characteristics was performed typing the EGFR. the Kras and ALK needed to establish the best therapeutic strategy. For the purposes of reaching the formulation of the diagnosis quickly we have elaborated the following algorithmic: 1 step Anamnesis family Rx toace, - pulmonary nodule-: 2 step Tc pulmonary Comparison previous confirms suspected-typing needle biopsy or excisional biopsy - negative 3 step typing Positive MRI, CT, + CT Abdomen + CT brain, PET,. 4 step surgery - radiative therapy - chemotherapy. the sequential approach provides for the definition of the nature of the *lesion and subsequent staging*

III. RESULTS

In the discussion of the morphology of the pulmonary nodule studied with diagnostic imaging method, the parameter of the morphological characteristic prevails as well as the diameter of the lesion which oscillated on average between 3-4 cm. but the criteria adopted did not accurately explain the nature of solid formation but hypothesize the benign or malignancy of the suspected lesion. Below these minimum diameters we obtained a safety with TC and RNM methods only in 50% of the observed cases, so in consideration of the high number of cases that were unresolved it was preferable to use more effective diagnostic methods. The instrumental examination of brushing bronchoscopy for the typing of pulmonary lesions has a diagnostic sensitivity and variability only in the presence of lesions greater than 2 cm in the bronchial endo site and in the basal and upper and apical lobe segments. In central lesions the bronchoscopy diagnosis with bronchial endo biopsy showed an accuracy of 95% of cases confirming the possibility of reaching the lesion and obtaining an accurate diagnosis. Transcutaneous biopsy has as methodical an optimal beneficial cost ratio with a successful examination in 100% of the cases observed. The use of thoracoscopy as an alternative to thoracotomy, due to its low mortality, and a mini invasiveness, we obtained a complete predictive value with a minimally invasive approach that required a short hospitalization. Moreover, the method is able to make a diagnosis or a pulmonary resection possible in those cases where the open thoracotomy is contraindicated, offering the possibility of performing a cuneiform resection of the suspicious nodule, confirming also in our experience a valid alternative. The study of the accurate definition of the N-factor (TNM staging) was necessary to define the therapeutic behavior. Therefore, an evaluation was carried out of both the non-invasive imaging methods (CTMR, PET) associated with the transophageal or trans tracheo bronchial echo, and with the invasive methods such as mediastinoscopy, needle biopsy, bronchial biopsy, thoracoscopy and thoracotomy. However, the criteria adopted and defined by diagnostic imaging have not always

been reliable, to define the need for histological cytological typing of mediastinal lymph nodes, whose positivity conditions the therapeutic diagnostic process (surgery or non-surgical therapy). However, in non-invasive diagnostics the study of the mediastinum for the stages lymph node action TC remains to date the most common diagnostic test also used in our experience, for ease of execution, availability affordability, repeatability. The PET examination with the recent development of new markers (18F fluorodeoxyglucose) since the latter accumulate in lesions in relation to glycolysis, are able to pinpoint the size of the lesion with the millimeter and the site. and therefore they are used as a method of greater effectiveness and specificity, especially in suspicious lesions of less than 2 cm. the invasive method of mediastinoscopy was the most used by us because of its greater reliability, sensitivity and specificity in MTS research, and was performed in all patients with a late diagnosis. In the surgical treatment of neoplasms performed with pulmonary resection, the most frequent complication was pneumothorax, which was present in obese patients, with multiple lesions in a single lobe. The treatment was that of the affixing of the pleural drainage whose high specificity and sensitivity was over 90%. The algorithm implemented allowed to obtain a rapid identification of the suspected lesions as well as to standardize diagnostic and therapeutic procedures. Biomolecular research on EGFR (80%), Kras (85%) and ALK (72%) confirmed the presence of genetic alterations by directing the diagnosis of the lesions towards a malignancy, then subsequently confirmed to the anatomopathological examination. Therefore, we have established inexplicable analyzes in defining the nature of the suspected lesion.

IV. DISCUSSION

In the presence of solitary or multiple pulmonary nodules, they proved to be effective in obtaining a diagnosis according to the literature and also in our experience, in the first phase the dynamic CT. Simple but sensitive test, which oriented the diagnosis towards the benignity of the nodule for the presence of an increase in density, after the administration of the MDC that was less than 15-20 HU. (13,14,15,16). PET proved to be a more accurate instrumental examination in the characterization of the nodule (17,18,19,20) Introducing the parameter of the analysis of the metabolic behavior of the lesion studied, and integrating the data provided by the TC. (21,22,23,24) The limits of the method remain the dimensions of the studied lesions that stop at 5-7 mm. Underneath them, nodules can not be detected at present (25,26,27,28). In this case, close follow-up is essential, as is the procedure of the histological examination with the percutaneous excisional biopsy, carried out to obtain a rapid histological diagnosis with a simplified procedure. the introduction of fine needles has made it possible to obtain cytology also on large mediastinal lymph nodes. (29,30,31,32) The histopathology classification adopted was that of the WHO referable to 4 main histologies with a prevalence in our case studies of ADC (adenocarcinoma > of 50% of the cases observed). In the differential diagnosis TTF-1 was used and p40 in order to preserve the biological material obtained for the predictive molecular investigations. (33,34,35,36) The necessity then to determine the mutational state of EGFR of ALK was dictated by the choice of the best therapeutic strategy. (37, 38,39,40) as well as to confirm the

malignancy of the lesion. In advanced patients, PET has demonstrated its effectiveness in detecting nodules below 2 cm metastatic, determining the site and spread of the disease. the evaluation of the general parameters such as the size of the nodule, the age, the clinical history, tobacco smoking, and excisional cytology were studied to define the criteria for the choice of therapeutic treatment. A general criterion was associated with the study of the mediastinum to determine the involvement of the same, to perform biopsies and to characterize the main lymph node stations, and to offer the possibility of performing supraclavicular biopsies, and of pre-scalic lymphatic adipose tissue (41,42,43,44) then of the VAT in general anesthesia for the staging of the patient with a diagnosis of pulmonary ca to which the introduction of an esophageal echography probe was associated allowed to identify the lymph nodes increased in volume in the mediastinum. (45,46,47,48) at its mini invasiveness today represents an important diagnostic and therapeutic evolution. The repetition of the examination was performed in patients in follow-up with a diagnosis of neoplasia. The method was well tolerated. (49,50,51) The criteria of fertility shared by many AAs were: the resectability of the lesion defined as a disease that is totally removed by surgical resection with curative indication, tolerance of surgical trauma, The margins of the resection defined by the uninjured anatomopathologist, the regional loco lymph node removal and the mts-free distal lymph nodes and the absence of neoplastic residues in the section rhyme (52,53,54) the development of minimally invasive diagnostic and therapeutic procedures have Minvasive surgery also made possible in major pulmonary resections, with the benefit of significant reduction in mortality and morbidity. However, endoscopic robotic surgery presents limitations such as tactile lesion, with a longer preparation of both operative times, as well as validation studies in terms of the oncological radicality of the method. Finally, in patients in whom resective treatment due to severe respiratory failure can not be performed, stereotactic radiotherapy (SABR) has been implemented, consisting of the application of a few high radiant gradient doses able to obtain a control of the disease in absence of toxicity with interesting results, in terms of positive responses.

V. CONCLUSIONS

Imaging diagnostics have improved accuracy by reducing diagnostic doubt in those pulmonary nodular lesions up to a maximum of 5-7mm. The radiological criteria for defining the lymph nodes of the mediastinum are essentially the size and the morphological appearance. However, at present a lymph node with dimensions exceeding 10 mm is established as positive, and this does not yet eliminate the execution of mediastinoscopy. The morphological criteria obtained by diagnostic imaging have shown great reliability in defining the capsular integrity, the tendency to lymph node conglomeration, and for the confirmation of the alteration of the structures. However, subsequent cyto-histopathological typing is required for true diagnostic accuracy. Finally, imaging diagnostics establish the eligibility criteria for the adjuvant treatment. The minimally invasive method / VAT. remains indicated in our experience when images suggest the suspicion of adenopathy

REFERENCES

- [1] Quanjer PH, Stanojevic S, Cole TJ, Baur X, Hall GL, Culver BH, Enright PL, Hankinson JL, Ip MS, Zheng J, Stocks J; ERS Global Lung Function Initiative. Multi-ethnic reference values for spirometry for the 3-95-yr age range: the global lung function 2012 equations. *Eur Respir J* 2012; 41:324-43. doi: 10.1183/09031936.00080312.
- [2] Pellegrino R, Brusasco V, Viegi G, Crapo RO, Burgos F, Casaburi R, Coates A, van der Grinten, Gustafsson P, Hankinson J, Jensen R, Johnson DC, MacIntyre N, McKay R, Miller MR, Navajas D, Pedersen OF, Wanger J. Definition of COPD: based on evidence or opinion? *Eur Respir J* 2008; 31: 681-2.
- [3] Vaz Fragoso CA, McAvay G, Van Ness PH, Casaburi R, Jensen RL, MacIntyre N, Yaggi HK, Gill TM, Concato J. Phenotype of spirometric impairment in an aging population. *Am J Respir Crit Care Med* 2016; 193: 727-35.
- [4] Ferlay J et al Cancer Incidence and mortality world wide: sources, methods and major patterns in GLOBOCAN 2012. *Int J Cancer* 2015; 136: E359
- [5] Malvezzi M et al European cancer mortality predictions for the year 2017, with focus on lung cancer *Annals of Oncology* 2017;0: 17.doi:10.1093/annonc/mdx033.
- [6] Travis WD, Brambilla E, Burke AP, Marx A, Nicholson AG. The Classification of Lung Tumors : Impact of genetic, clinical and radiologic advances since the 2004 classification. *J Thorac Oncol* 2015 10:1243-- 1260.
- [8] Detterbeck FC, Boffa DJ, Kim AW, Tanoue LT. The Eighth Edition Lung Cancer Stage Classification *Chest* 2017; 151(1):193--203
- [9] Aberle DR et al; National Lung Screening Trial Research Team; Reduced lung cancer mortality with low dose computed tomographic screening *N Engl J Med* 2011 365: 395--409
- [10] Graziano G, A Dicaldo (2017). COMPLICATIONS IN LAPAROSCOPIC CHOLECYSTECTOMY *INTERNATIONAL JOURNAL OF CURRENT ADVANCED RESEARCH*, vol. 6, p. 3855-3859, doi: <http://dx.doi.org/10.24327/ijcar.2017.3859.0382>
- [11] Graziano G, e al (2015). The Neuroendocrine Cancer. Personal Comments and Operational Remarks. *JOURNAL OF SURGERY AND SURGICAL RESEARCH*, vol. 1, p. 53-58, doi: DOI: 10.17352/2455-2968.00001418.
- [12] GRAZIANO G, et al (2017). ROLE OF GENETIC MUTATIONS IN THE DIAGNOSIS OF GALLBLADDER NEOPLASMS . *INTERNATIONAL JOURNAL OF RECENT SCIENTIFIC RESEARCH*, vol. 8, p. 20908-20913, DOI: <http://dx.doi.org/10.24327/ijrsr.2017.0810.0982>
- [13] De Marinis F e Gridelli C :Linee Guida Associazione Italiana di Oncologia Toracica per la gestione integrata del paziente con tumore polmonare. Edizione 2016
- [14] Masters GA et al. Systemic Therapy for stage IV NSCLC: ASCO Clinical Practice Guideline Update. *J Clin Oncol* 2015; 33:3488--3515.
- [15] Fruh M et al; Small Cell Lung Cancer: ESMO Clinical Practice Guidelines. *Annals of Oncology* 2013; 24 (suppl 6): v199--v1105.
- [16] National Comprehensive Cancer Network Clinical Practice Guidelines In Oncology (NCCN Guidelines): Small Cell Lung Cancer Version 4.2017 (Feb 23,2017)
- [17] Hirsch F et al. Lung cancer: current therapies and new targeted treatments; *The Lancet* 2017;(389)21:299--311
- [18] .GRAZIANO G, e al (2016). Vascular Thoracic Fibrous Adipose Tissue (New Disease). *JOURNAL OF PHARMACEUTICAL AND BIOMEDICAL SCIENCES*, vol. 6, p. 419-424, , doi: <http://dx.doi.org/10.20936/jpbms/160265>
- [19] Vansteenkiste J et al. Consensus Conference on Lung Cancer: Early Stage Non --Small Cell Lung Cancer consensus on diagnosis, treatment and follow up. *Annals of Oncology* 2014; 25:1462--74
- [20] Burdett S et al. Adjuvant chemotherapy for resected early stage Non Small Cell Lung Cancer. *Cochrane Database Systemic Rev* 2015; Mar 2 ; 3CD011430.doi:10.1002/ 14651858.CD011430
- [21] Eberhardt WEE et al ESMO Consensus Guidelines: Locally advanced stage III Non--Small Cell Lung Cancer. *Annals of Oncology* 2015; 26(8): 1573--1588
- [22] Yoon SM et al. Therapeutic management options for stage III non--small cell lung cancer. *World Journal of Clinical Oncology* 2017 (feb) 10; 8(1): 1--20
- [23] National Comprehensive Cancer Network Clinical Practice Guidelines In Oncology (NCCN Guidelines): Non Small Cell Lung Cancer Version 4.2017 (Jan 18,2017)
- [24] Novello S et al. Metastatic non--small--cell--lung cancer: ESMO Clinical Practice Guidelines for diagnosis, treatment and follow up. *Annals of Oncology* 2016; 27 (suppl 5): v1--v27
- [25] Crinò L et al. Linee Guida Associazione Italiana di Oncologia medica (AIOM) Neoplasie del Polmone 2016